Segmentation of Skin Lesions and Related Structures -An Analytical Study

A.A.Haseena Thasneem
Research Department of Computer Science
Sadakathullah Appa College, Tirunelveli, India

R.Mehaboobathunnisa
Research Department of Computer Science
Sadakathullah Appa College, Tirunelveli, India

Dr.M.Mohamed Sathik
Principal & Research Coordinator
Research Department of Computer Science
Sadakathullah Appa College, Tirunelveli, India

Dr.S.Arumugam
Principal
Nandha Engineering College
Erode, India

Abstract - Automated computer aided analysis and interpretation has become an important research area and accurate border detection is the first and foremost step for any analysis. Identification of the diseased/abnormal portion of the skin is possible only by accurate delineation methods. This paper critically reviews and summarizes some of the medical image segmentation techniques in literature. The various detection methods applied to segmenting skin lesions and structures such as pigment networks and irregular streaks have been discussed. All the methods discussed provide meaningful visualization of these structures and irregularity detection.

Keywords: dermoscopy, segmentation, melanoma, streaks, pigment networks

I. INTRODUCTION

Skin cancers can be classified into melanoma and non-melanoma. Malignant Melanoma (MM) is supposed to be the third most frequent type of skin cancer. Diagnosing melanoma early in its initial stages is essential because its prognosis is directly proportional to the depth of neoplasm [1].Early diagnosis of melanoma helps in reducing the morbidity and cost of therapy.To facilitate the early detection of melanocytic skin lesions, a variety of non-invasive imaging modalities for image acquisition which complement the naked-eye detection has been developed. They are the Total Body Photography (TBP), Dermoscopy (Epiluminescence Microscopy/Dermatoscopy), Confocal Scanning Laser Microscopy (CSLM), and Ultrasonography, to name a few. Nowadays,Dermatoscope has become a standard tool for capturing skin images.It is defined as a non-invasive diagnostic technique for the in vivo observation of pigmented skin lesions, allowing a better visualization of surface and subsurface structures[13].

Dermoscopes are of two types: Non Polarised Dermoscope (NPD) and Polarized Dermoscope(PD).NPD uses oil or alcohol as interface with refraction index same as that of skin to optically link the stratum corneum with the glass plate of dermoscope. This interface allows more light to penetrate the skin and its deep structure can be visualized[13]. PD has a polarized light filter that captures the backscattered light from the deeper levels of the skin without the need for direct contact with the skin. Dermoscopy increases the diagnostic accuracy, reduces the number of medically unnecessary biopsies and is relatively inexpensive.It also identifies dozens of morphological features such as pigment networks, dots/globules, streaks, blue- white areas, blotches etc.

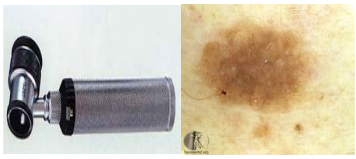

(a) (b)

Figure.1 a)Dermatoscope b)Dermoscopic Image

To further improve the diagnostic accuracy, fully automated computer assisted melanoma diagnostic systems have been developed with improved specificity and sensitivity. This however is not a substitute for trained dermatologists but will be of great help to less trained practitioners in remote clinics. This idea was introduced in the early 1990s. These systems aid in segmentation of lesion from the acquired image, feature extraction and lesion classification. Accurate segmentation forms the basis for feature extraction, classification as well as for the extraction of other important clinical features like atypical pigment networks, globules, blue-white areas etc. Structure analysis of dermoscopic images has been dealt very early by Fleming [22].Three pattern recognition algorithms for globular, reticular, and blue veil pattern diagnosis has been implemented in [18].Dots/globules [13] are sharply circumscribed, usually round or oval variously sized black, brown or gray structures. The blue-whitish veil is a gray-blue to whitish-blue pigmentation associated with pigment network alterations, dots/globules and streaks. Automatic detection of blue-white veil and related structures has been reported by Celebi et al. in [14].Challenges as suggested by Celebi [17] for border detection are low contrast between the surrounding skin and the lesion, fuzzy and irregular lesion border, intrinsic artifacts such as cutaneous features (air bubbles, blood vessels, hairs, and black frames).

In this paper are given a few of the segmentation techniques that help in detecting skin lesions, pigment networks and streaks from dermoscopic images. Section II overviews skin lesion detection algorithms, Section III discusses pigment network detection algorithms and Section IV presents streak detection.

II. DETECTION OF SKIN LESIONS IN DERMOSCOPY

The diagnostic algorithms and segmentation techniques help in determining whether the particular lesions are melanocytic and should be biopsied. The basic algorithm based on score calculation is the ABCD rule on dermoscopy[3] , CASH[4], Menzies method [29] and 7-point checklist[5] and on gestalt-based is the pattern analysis[6]. L.Xu et al.[7] proposed a three step automatic segmentation method. Preprocessing step involves the transformation of RGB color coordinates to L*a*b* color coordinates since color has to be represented with less redundancy to find the color difference($\Delta L^*, \Delta a^*, \Delta b^*$).The color distance between the image pixels and background is computed using $\Delta E=(\Delta L^{*2}+\Delta a^{*2}+\Delta b^{*2})^{1/2}$ .Background color is the median color of pixels(10x10) in the four corners of the image .Also Gaussian function is used to smooth the image. In initial segmentation step, double thresholding is applied to reduce the number of noisy regions. Edge detection as a refinement of initial segmentation uses a closed elastic curve to expand or shrink the initial contour. Double thresholding combined with edge detection helps in detecting small fraction of edges that lie on or near the boundary of lesion.

Schmid Ph.et al. [8] has presented a CAD system for pigmented skin lesions. Preprocessing step as in Figure 2 incorporates an efficient hair removal algorithm. After color transformation of RGB space to L*u*v* color space, a morphological closing is applied. A threshold value is then applied to the difference between the luminance before and after closing. Two detection algorithms have been developed. One is Orientation-Sensitive Fuzzy C Means (OS-FCM) which is an iterative algorithm.

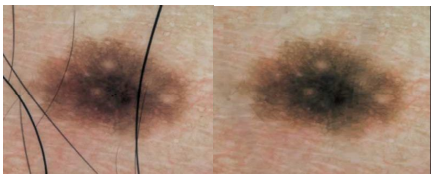

(a) (b)

Figure. 2 a) Image with hair b) after hair removal.

Using the Karhunen-Loeve Transform (KLT), the two principal components with highest variance are computed.Number of clusters and cluster centers are randomly initialized. Fuzzy membership function and

covariance matrix of each data sample to each cluster is calculated. The clustering converges leading to the segmentation result. Another method is based on nonlinear isotropic diffusion and morphological flooding and the segmented result is as shown in Figure.3b.The clustering techniques produced better results than isotropic diffusion and morphological flooding and the results for FCM and OS-FCM are shown in Figure.3c and 3d .



(a) (b)

(c) (d)

Figure.3 a) original image b) segmented output for anisotropic diffusion and morphological flooding c) output for FCM d) output for OS-FCM

To ensure accurate border detection, images should be chosen in such a way that they neither have too much hair nor have insufficient contrast between lesion and background as suggested by Celebi et al. [10].They have developed an automatic segmentation algorithm, which includes a preprocessing step,a segmentation algorithm JSEG based on Deng.Y [11] followed by a post processing step to remove the isolated regions and merge the remaining regions. Preprocessing is by smoothing an image using a color median filter of 11x11 kernal. Variance- based quantization method is used for color reduction and Otsu's method is used for lesion localization.The J value gives the ratio of interclass to intraclass variability based on Fisher's multiclass linear discriminant analysis. JSEG algorithm works in two phases. In the color quantization phase, the colors are quantized and replaced with its class label to differentiate the neighbouring regions in an image. For an image with several homogeneous regions, the value of J is large. In the second phase, based on the J images, the initial regions are merged in the L*u*v* color space for the segmented result. A modified version of JSEG algorithm has been proposed by the same author Celebi et al [12] which includes a faster and effective quantization algorithm, the variance-based quantization algorithm in the first phase.

Four different methods for segmentation of melanoma were proposed and evaluated by M.Silveira et al.[15]which includes an improvement over Adaptive Thresholding (AT), Adaptive Snakes(AS), Expectation-Maximization, Level-Set(EM-LS) and Fuzzy-Based Split-and-Merge algorithm(FBSM). Preprocessing was by a morphological closing filter using a disk (r=5) as the structuring element and also additionally with a median filter to remove hairs. To remove the four corners Otsu's method was used followed by elimination of binary components as shown in Figure.4a and 4b. In the improved version of AT, lesion segmentation is obtained by comparing each pixel with a threshold T. The threshold is automatically fixed from the histogram of the selected color component; h_i (k) .The color component with highest entropy is selected as

$$i^* = \arg \{\max S(i)\} \quad (1)$$

where S (i) = - $\sum_{k=1}^{L} h_i(k) \log [h_i(k)]$

(a) (b)

Figure. 4 preprocessing (a) mask (b) after corner and hair removal

To discard the influence of outliners in active contours, the authors of this paper had proposed the Adaptive Snake (AS) model. Edge linking is used to detect the contour segments (stroke) and EM algorithm helps in approximating a subset of them by assigning a confidence degree with each stroke. EM updates the elastic contour iteratively. Initialization of the snake is automatic. The third method proposed was the EM-LS as an extension of Chan by assuming that the intensities inside and outside C are modeled by probability density functions p_1 and p_2 respectively. Gaussian mixture model is used for the density functions and is estimated using EM algorithm at each iteration of level set. The unsupervised and fully automatic FBSM method segments natural color images by extracting the L*a*b* color features and geometrical features as the texture features. This split and merge includes simple splitting, local merging, global merging and boundary refinement steps. A fuzzy based homogeneity measure is used to calculate the similarity of adjacent regions. FBSM showed better results for fully automated segmentation.EM-LS and AS also provides good segmented output but require user interaction.

Another fast and unsupervised border detection method based on Statistical Region Merging [16] for dermoscopic images has been proposed by Celebi et al. [17].This method is based on an inference problem, in which the image is treated as an observed instance of an unknown theoretical image .With |I| pixels in an image and g=256 for a color image, this algorithm is based on a merging predicate and the order of merging. Any two regions (*R* and *R'*) in an image *I* shall be merged if and only if they satisfy the statistical test condition (2)

$$P(R, R') = \begin{cases} \text{true; } |R - R'| \le \sqrt{b^2(R) + b^2(R')} \\ \text{false; otherwise} \end{cases} \quad (2)$$

where $b(R) = g\sqrt{\frac{1}{2Q}\left(\frac{1}{R} + \frac{1}{R'}\right)\ln\frac{2}{\delta}}$

$\delta = \frac{1}{6|I|^2}$ and Q – Quantification factor

The scale of segmentation increases with the value of Q. The advantage of this algorithm is its implementation speed. It could handle noisy and occluded images with multiple channels.

Perceptually oriented skin tumor detection is an Improved Region based Active Contour (IRAC) model proposed by Q.Abbas et al. in [19].This method is specifically designed to segment multiple regions. The JCh (lightness, chroma, hue) uniform color space is the color system adopted because of its uniformity and adaption to human perception. Moreover the homomorphic filtering is used to reduce the specular reflection and a contrast improvement is applied to facilitate the segmentation process followed by hair removal by using the derivative of Gaussian and inpainting technique. A rough segmentation of the tumor image is obtained first by a threshold automatically determined by the minimum-error technique. The IRAC automatically initializes the level set curves by a blob technique and determines the required parameters for convergence. This method overcomes the limitations of contour models like the single level set initialization, overlapping contours and fixed regularization parameters. The segmented output (blue) for IRAC algorithm and manual segmentation by expert (red) is shown in Figure.5.

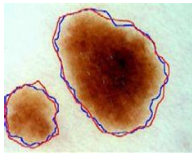

Figure.5 Multi tumor segmentation (blue) by IRAC

An improved version of Fuzzy C means and mean shift has been proposed in [26], called the Anisotropic Mean Shift based FCM (AMSFCM) Segmentation. The cluster centers and fuzzy memberships are initialized randomly.Then the cluster centers are computed iteratively and new memberships are calculated as in FCM. The new method AMSFCM proposed estimates the density with anisotropic kernals for each pixel and calculates the mean vector iteratively till a threshold is reached. Pixels with less Mahalanobis distances are merged until the membership function converges iteratively to obtain the required segmentation.

The most straightforward and easiest segmentation technique in literature so far is the thresholding technique. But its performance critically depends upon the choice of threshold. Due to the uncertainty and color fuzziness associated with the borders, fuzzy logic based thresholding approaches have gained much popularity.Type2 fuzzy logic is a new technique proposed [27]for nevus images ,which provides better performance in determining the threshold value. This works similar to the histogram thresholding algorithm except in calculating the threshold value which partitions the image into two homogeneous regions. The process is defined as such:

choose the shape of membership function μ_x and hedge parameter α. Initialise the center of μ_x on the histogram. Slide μ_x from minimum to maximum gray level value. Calculate maximum ultrafuzziness value from the lower and upper membership functions. The optimal threshold value is obtained from the position of center of μ_x. This provides good results which are shown in Figure.6a and 6b when compared with other segmentation methods in literature.

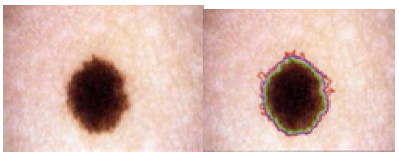

(a) (b)

Figure.6 a) original image b) Nevus borders detection using Type 2 fuzzy (blue)

In [20] Wavelet Network (WN) based segmentation of skin lesion has been introduced. WN combines the advantages of wavelet transforms and neural networks and requires no training. The number of wavelets, scale and shift parameters can be specified in advance since Fixed Grid Wavelet Network(FGWN) is used .The only parameter that needs to be calculated are the weight coefficients which is done by Orthogonal Least Square algorithm(OLS) . FGWN is a three layer network with one hidden layer. The FGWN structure is determined first by normalizing the input data. After appropriate selection of Mexican hat mother wavelet, a wavelet lattice is formed. This lattice is a hypershape of huge dimension and undergoes two stages of screening to select effective wavelets. To reduce the redundancy and select the best subset from the wavelet matrix, an iterative deterministic algorithm, the OLS is used. R, G, B values are given as inputs to the network structure and the output is a binary segmented image as in Figure.7

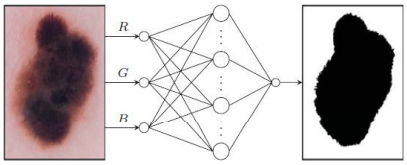

Figure. 7 FGWN for segmentation

A combination or fusion of different threshold methods are proposed in [21] called ensembles of thresholding. The four thresholding methods fused are Huang and Wang's fuzzy similarity method, Kapur et al's maximum entropy method, Kittler and Illingworth's minimum error thresholding method and Otsu's clustering based method. The fusion method showed better segmented results Figure. 8(g) than their individual segmentation results in Figure.8 (c to f)



(a) (b) (c) (d)

(e) (f) (g)

Figure .8 a) original Image b) blue channel c) Huang and Wang's(T=183) d) Kapur et al's method(T=178) e) Kittler and Illingworth's(T=192) f) Otsu's method(T=137) g) Fusion segmented output (green)

III. DETECTION OF PIGMENT NETWORKS IN DERMOSCOPY

A typical pigment network [13] is characterized by a light- to dark-brown pigmented, regularly meshed and narrowly spaced network distributed more or less regularly throughout the lesion and usually thinning out at the periphery. An atypical pigment network with high specificity for the diagnosis of melanoma is characterized by a black, brown, or gray, irregularly meshed network, distributed more or less irregularly throughout the lesion and usually ending abruptly at the periphery. The lines of an atypical pigment network are often thickened.

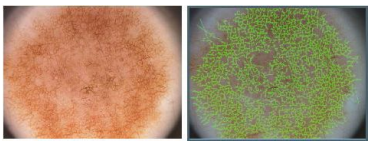

(a) (b)

Figure.9 a) original image b) pigment network by directional filters

Two texture algorithms for pigment network detection namely Laws Energy mask and Neighborhood Gray-Level Dependence Matrix (NGLDM) were compared in [2].Texture is the coarseness in an image. Laws Energy Mask creates a two dimensional mask by convolving a vertical vector with a horizontal vector.N^2 masks can be created from a vector of size N. The luminance image was convolved with the masks and the image elements were squared, added, and averaged. These energy measures along with an optimized threshold for color filtering detect the pigment network. NGLDM developed by Sun and Wee is a rotation invariant method for the analysis of smoothness in skin tumors. Pigment networks were detected using small number emphasis,large number emphasis,non uniformity,entropy and second moment. Laws energy mask performed better than NGLDM.

A system for automatic detection of pigment network using Directional filters has been proposed in [25] .Regions with pigment networks are detected to provide enhancement using directional filters and geometrical properties. A bank of directional filters were used to detect linear strokes in a specific direction.These directional filters are composed of N+1 bank of filters, each one of them tuned to a specific orientation $\theta_i \in [0,\pi]$,i=0,….,N. The image is filtered by each directional filter. The output of the ith directional filter is given by the convolution of impulse response of each filter and the image. A difference of the Gaussian was chosen as the impulse response function for better enhancement. A combinational output of N+1 filter are got from the maximum output at each pixel. After filtering a threshold is applied to find the pixels that form the pigment network. All connected components in the binary image are extracted by using the 8 connectivity as shown in Figure 9b.

Another method based on supervised machine learning and structural analysis technique was proposed in [9].A set of rules when applied over an image (Figure.10a) forms a mask with the pixel candidates to be part of the pigment network. Structural analysis is carried over this mask (Figure.10b) and makes a decision as to whether it is a pigment nework or not. If it was a pigment network again a mask is created which is the pigment network mask and Figure 10c shows the output pigmented network. A sensitivity of 86% and specificity of 81.67% is obtained even when there are hairs.

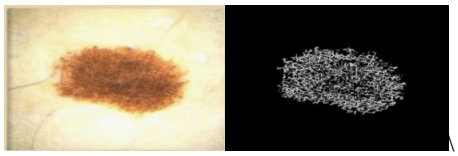

(a) (b)



(c)

Figure.10 a) original image b) mask with pixel candidate as part of the pigment network c) detected pigment network using mask

A pigment network is composed of holes and nets. [28] describes a hole detection method using graphs. Preprocessing step includes: automatic segmentation using Random Walker algorithm, sharpening using the unsharp mask followed by the color transformation. Green channel was chosen as the luminance image. LoG filter is used to detect sharp changes in intensity and the resultant image is a binary image which is converted into a graph.Loops or cyclic subgraphs are found in the graph and according to its density classification as to whether holes are present or not is done.Net detection is by first applying LoG on the green channel of the image and by applying an automatic threshold,the net mask is created. This mask is skeletonized further by overlaying the net mask on the original image.

IV. DETECTION OF IRREGULAR STREAKS IN DERMOSCOPY

Streaks [13] are brownish-black linear structures of variable thickness. These streaks are regular or irregular, more or less converging, which are observed throughout a lesion. The term streaks include radial streaming, radial streaks and pseudopods. Although streaks are found in benign and malignant melanocytic skin lesions, the presence of irregular streaks strongly indicates malignancy.

Irregular streak detection and analysis have been proposed in [23],[24].Segmentation is performed using Random Walker method and the orientation of the lesion ,the angle between the x-axis and the major axis of the ellipse is found. The image is rotated to align with the major axis horizontally representing the lesion growth direction. The lesion is resized for uniform representation and converted to L*a*b* color space and L* is used for further single plane analysis. To find region of interest, which is the boundary of the lesion where the streaks are found, distance transform of the lesion mask is calculated from the lesion border. One third of the length of minor axis is used to determine the region of interest. Linear structures are detected using Laplacian of Gaussian (LoG) filters. Enhancement of the orientation image using a Gabor filter is performed followed by a geometric investigation that identifies valid streaks from false positives.

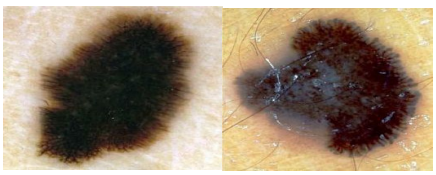

(a) (b)

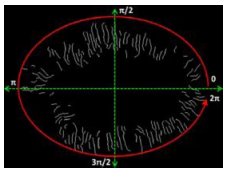

(c)

Figure.11 a) Radial streaming streaks b)pseudopod streaks c) Valid streaks with major and minor axis in green and boundary thickness in red

V. CONCLUSION

This paper reviewed various detection techniques in the diagnosis of skin lesions and its related structures like the pigment networks and streaks in dermoscopic images. Use of appropriate preprocessing techniques will aid the segmentation process far better. Eventhough the promising computer assisted diagnostic systems are limitedly employed in speciality clinics, it should be viewed only as an adjunctive tool and not a first line of diagnostic technology. Lastly, it is important to remember that all these tools should not be used in isolation on the management of patients with suspicious skin lesions. Clinical presentation, personal and family history should also be considered into the overall diagnostic decision process.

REFERENCES

[1] Darrell S. Rigel, MD; Julie Russak, MD; Robert Friedman, MD,"The evolution of melanoma diagnosis: 25 years Beyond the ABCDs" *CA Cancer J Clin*;60:301–316,American Cancer Society,Inc,2010.

[2] M.Anantha, R.H.Moss, .V.Stoecker," Detection of pigment network in dermatoscopy images using texture analysis",*Comput.Med.Imaging Graph*. 28, 225–234, 2004.

[3] Nachbar F,Stolz W,Merkle T et al,"The ABCD rule of dermatoscopy.High prospective value in the diagnosis of doubtful melanocytic skin lesions".*J Am Acad Dermatol* 30:551-559,1994.

[4] Henning JS,Duzsa SW,Wang SQ,et al,"The CASH (color,architecture,symmetry,and homogeneity) algorithm for dermoscopy" *J Am Acad Dermatol* 56:45-52,2007.

[5] Argenziano G, Fabrrocini G,Carli P et al ,"Epiluminescence microscopy for the diagnosis of doubtful melanocytic skin lesions.Comparision of the ABCD rule of dermatoscopy and a new 7-point checklist based on pattern analysis".*Arch Dermatol* 134:1563-1570,1998.

[6] Pehamberger H,Steiner A,Wolff K,"In vivo epiluminescence microscopy of pigmented skin lesions.I.Pattern analysis of pigmented skin lesions " *J Am Acad Dermatol* 17:571-583,1987.

[7] Xu.L,M.Jackowski,A.Goshtasby,D.Roseman,S.Bines,C.Yu,A.Dhawan,A.Huntley,"Segmentation of skin cancer images",*Image and vision computing* 17,65-74,1999.

[8] Ph. Schmid-Saugeon, J. Guillodand J.-Ph. Thiran, "Towards a Computer Aided Diagnosis System for Skin Cancer", *Computerized Medical Imaging and Graphics*, vol. 27, no. 1, pp. 65- 78, January 2003.

[9] Jose LuisGarcíaArroyo n, BegoñaGarcíaZapirain" Detection of pigment network in dermoscopy images using supervised machine learning and structural analysis", *Computers inBiologyandMedicine*44,144–157,2014.

[10] M. E. Celebi, H. A. Kingravi, B. Uddin, H. Iyatomi, A. Aslandogan, W. V. Stoecker, and R. H. Moss,"A Methodological Approach to the Classification of Dermoscopy Images," *Computerized Medical Imaging and Graphics*, vol. 31, no. 6, pp. 362-373, 2007.

[11] Deng Y,Manjunath BS."Unsupervised segmentation of color-texture regions in images and video", *IEEE Trans Pattern Anal Machine Intell* ;23(8):800-10,2001.

[12] Celebi ME, Aslandogan YA, Stoecker WV et al. "Unsupervised Border Detection in Dermoscopy Images" , *Skin Research and Technology* ; 13(4): 454-462.2007.

[13] www.dermoscopy.org

[14] Celebi ME, Iyatomi H, StoeckerWV. et al. "Automatic Detection of Blue-White Veil and Related Structures in Dermoscopy Images", *Computerized Medical Imaging and Graphics* ; 32(8): 670- 677,2008.

[15] Margarida Silveira, Jacinto C. Nascimento, Jorge S. Marques, André R. S. Marçal, Teresa Mendonça, Syogo Yamauchi, Junji Maeda, and Jorge Rozeira "Comparison of Segmentation Methods for Melanoma Diagnosis in Dermoscopy Images", IEEE *journal of selected topics in signal processing*, vol. 3, no. 1, february 2009.

[16] Nock R. and Nielsen F. "Statistical Region Merging",*IEEE Trans. on Pattern Analysis and Machine Intelligence*, 26(11): 1452-1458,2004

[17] M. E. Celebi, H. A. Kingravi, H. Iyatomi, A. Aslandogan, W. V. Stoecker, R. H. Moss, J. M.Malters, J.M.Grichnik, A. A. Marghoob, H. S. Rabinovitz, and S. W. Menzies, "Border Detection in Dermoscopy Images Using Statistical Region Merging", *Skin Research and Technology*, vol. 14, no. 3, pp. 347-353, 2008.

[18] A. GolaIsasi,B.Garcı´a Zapirain,A.Mendez Zorrilla "Melanomas non-invasive diagnosis application based on the ABCD rule and pattern recognition image processing algorithms" *Computers in Biology and Medicine* 41 742–755,2011.

[19] Q. Abbas, M. E. Celebi, and I. F. Garcia, "A Novel Perceptually-Oriented Approach for Skin Tumor Segmentation," *International Journal of Innovative Computing, Information and Control*, vol. 8, no. 3, pp. 1837-1848, 2012.

[20] Amir Reza Sadri, Maryam Zekri, Saeid Sadri, and Niloofar Ghaisari, Kolahdouzan.F."Segmentation of Dermoscopy Images Using Wavelet Networks", *IEEE Transaction on Biomedical Engineering*, 2012.

[21] M.Emre Celebi,Quan Wen,Sae Huang,Hitoshi Iyatomi,Gerald Schaefer,"Lesion border detection in dermoscopy images using ensembles of thresholding methods"*Skin Research and Technology*, 19(1): e252-e258, 2013.

[22] M. G. Fleming et al., "Techniques for a structural analysis of dermatoscopic imagery," *Comput. Med. Imag. Graph*., vol. 22, no. 5, pp. 375–389, 1998.

[23] M. Sadeghi, T. K. Lee, D. McLean, H. Lui, and M. S. Atkins, "Oriented pattern analysis for streak detection in dermoscopy images", *Med. Image Comput. Comput.-Assist. Intervent.* ,pp.298–306,2012.

[24] Maryam sadeghi,Tim K. Lee,David Mc Lean,Harvey Lui, and M. Stella Atkins,"Detection and analysis of irregular streaks in dermoscopic images of skin lesions",*IEEE Transactions on medical Imaging*,Vol.32,No.5,May 2013.

[25] Catarina Barata,Jorge S. Marques and Jorge Rozeira,"A System for the detection of pigment network in dermoscopy images using directional filters",*IEEE Transactions on Biomedical Engineering*, Vol.59, No.10, October 2012.

[26] H. Zhou, G. Schaefer, A. Sadka, and M. E. Celebi, "Anisotropic Mean Shift Based Fuzzy C-Means Segmentation of Dermoscopy Images", *IEEE Journal of Selected Topics in Signal Processing*, vol. 3, no. 1, pp. 26-34, 2009.

[27] M. Emin Y¨uksel, and Murat Borlu," Accurate Segmentation of Dermoscopic Images by Image Thresholding Based on Type-2 Fuzzy Logic", *IEEE transactions on fuzzy systems*, vol. 17, no. 4, august 2009.

[28] M.Sadeghi,M.Razmara,T.K.Lee,M.S.Atkins,"A novel method for detection of pigment network in dermoscopic images using graphs",*Comput.Med.Imaging Graph*,35,137–143,2011.

[29] Menzies SW, Ingvar C, McCarthy WH. "A sensitivity and specificity analysis of the surface microscopy features of invasive melanoma" , *Melanoma Res*;6:55-62,1996.