Harmonized Meagerly Model for Histopathological Image Illustration and Cataloging

G. Elawarasi
PG Scholar, Sri Sai Ram Engineering College, Chennai

Abstract - Skin disease affect around 3% of the population worldwide. They tend to be itchy and spread over the body easily. Among them, Psoriasis is a common chronic, inflammatory skin disease characterized by scaly patches. It causes severe skin inflammation and the treatment for such cases are determined based on the severity evaluated by Psoriasis Area Severity Index (PASI) scoring system. Currently. these scores are estimated visually and hence suffers from inter and intra-observer difference. This severely affects the way, the disease is treated. Our proposed system focuses on segmentation and scaling of 2D digital images of Psoriasis. This computer assisted system removes erythematic from the selected psoriasis image and considers other skills cells for analysis and treatment. The "Feature Space Scaling Algorithm" uses color, contrast and image texture along with a combination of SVM classification filters and Markov random fields to come up with a treatment solution. the algorithm is tested with different skins under different lighting condition and is proved to be reliable.

I. INTRODUCTION

The key messages from the various experiments described in Sections IV-B–IV-F. first aim is to validate central hypothesis, that a multi-channel simultaneous sparsity model can be used to represent and classify colorhistopatho logical images. Accordingly, demonstrate the improvements offered by the proposed approach (SHIRC) overstate-of-the-art alternatives. While the expected classification trends are seen for the ADL data set, the IBL data set presents a challenging scenario where the SHIRC method, if applied directly, could lead to worse performance than a traditional SVM classifier. then show more elaborate experimental results, in the form of confusion matrices and ROC curves, to demonstrate that LA-SHIRC, the locally adaptive variant of our SHIRC, indeed out performs all other techniques by creating richer dictionaries that are synthesized by combining local image blocks. A new experimental insight is gained in that LA-SHIRC offers high classification accuracy even with a limited number of training images. Next, show the performance of LA-SHIRC as a function of the number of local blocks to highlight the complementary benefits of the local block selection strategies. Finally, we discuss the following issues of practical interest the role of image features for classification, a comparison of algorithm runtimes and the ability of the proposed algorithms to reject images from unseen classes. In order to facilitate the use of the proposed algorithms for medical image classification and other multi-variety multi-task classification problems. the psoriasis impact over the segmentation of implementation of the non-contagious analysis over the various featured image.the scope of the project and the aim is to provide such treatments analysis over psoriasis diseases.

II. LITERTURE REVIEW

Tendon disorders are a major problem in competitive and recreational sports. Does the histopathology underlyingtheseconditions explain why they often prove recalcitrant to treatment? We reviewed studies of histopathology of symptomatic Achilles, patellar, extensor carpi radialis brevis and rotator cuff tendons in sportspeople.the literature indicates that normal tendons appear glistening white to the naked eye and microscopy reveals a hierarchical arrangement of collagen fibres in tightly-packed parallel bundles with a characteristic reflectivityunder polarized light. Stainable ground substance is absent and vasculature is inconspicuous. Tenocytes aregenerally in conspicuous, and fibroblasts and myofibroblasts absent.In stark contrast, tendons of symptomatic athletes appear grey and amorphous to the naked eye and microscopyreveals discontinuous and disorganized collagen fibers that lack reflectivity under polarized light. This is
associated with an increase in mucous ground substance which is confirmed with alien blue stain. At sites of maximal mucous change tenocytes, when present, are plump and chondroid in appearance (exaggeratedfibrocartilaginous metaplasia).These changes are accompanied by increasingly conspicuous cells within

thetendon tissue and most have a fibroblastic or myofibroblastic appearance (smooth muscle actin is demonstratedby using an avidin biotin technique).Maximal cellular proliferation is accompanied by prominent capillaryproliferation.

III. SYSTEM ANALYSIS

System Analysis is a combined process dissecting the system responsibilities that are based on the problem domain characteristics and user requirements.

IV. SYSTEM ARCHITECTURE

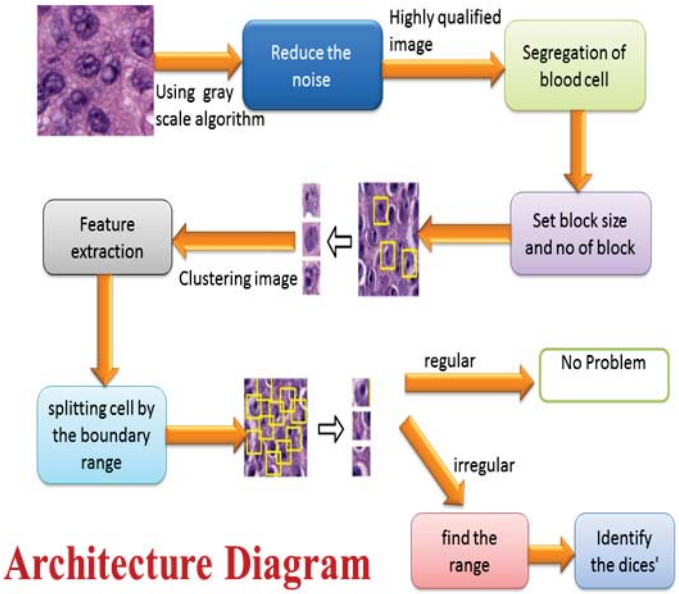

Figure 1 System Architecture

4.1 EXISTING SYSTEM

In many cases, the existing system portrays that the early leg diseases (psoriasis) diagnosis is difficult and may be confusing. So hence it may affect treatments to the patients at a wide range of inflamed skin. usually this chronic inflammatory skin disease have a discrete psoriasis skin pattern with poor border definition, which may not be easy to analyze and figure out .It has a variety of clinical presentations, most of which eventuate into assessment of psoriasis severity and often on the area where scaly patches of itchy skin presents. The exact cause of psoriasis is unknown, but it is recognized that psoriasis is heritable and genetics.

Disadvantages of Existing System

- Sequential queries are not possible in this system.
- One column per aggregation only achieved in this system

4.2 PROPOSED SYSTEM

Psoriasis skin segmentation images were digitally captured under controlled environment in the proposed system. that certain normalization technique can be employed to distinguish the for WND-CHARM of psoriasis skin diseases infecting the further analysis symptoms of psoriasis. In clinical diagnostic, dermatologist usually groups the psoriasis skin segmentation pattern in order to reduce the problem of segmenting in the proposed concept. there are several pre-processing techniques, filtering techniques and Histopathological processing techniques employed in this image segmentation process to eradicate the affected areas of psoriasis.

Advantages of Proposed system:

- Multicolumn in single aggregation can possible in this system
- It's a Multidimensional, fastest and secured system.

V. IMPLEMENTATION AND RESULTS

Implementation is the stage of the project when the theoretical design is turned out into a working system.

5.1 MODULE DESCRIPTION

- Image Training Module
- Edge Detection Module
- Object Identification Module
- Object Recognition Module
- Infection Detection Module

IMAGE TRAINING MODULE

An initial module to load the images and train the system with the initial set of images. The module system will identity the images. The user will be permitted to access the system through a secure login system which can be considered as an Authentication Module

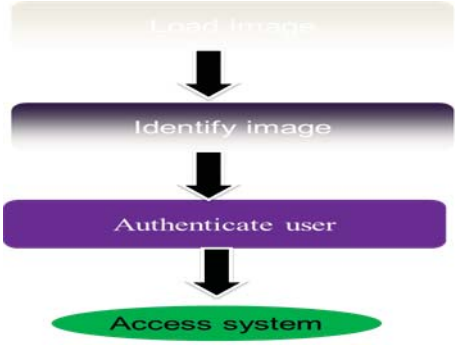

Figure 2 Image Training

EDGE DETECTION MODULE

The module,the edges of the images will be identified and marked in this module the discontinuities are abrupt changes in pixel intensity which characterize boundaries of objects in a scene.Classical methods of edge detection involve convolving the image with an operator which is constructed to be sensitive to large gradients in the image while returning values of zero in uniform regions.The basic principle is, Not all edges involve a step change in intensity. Effects such as refraction or poor focus can result in objects with boundaries defined by a gradual change in intensity.

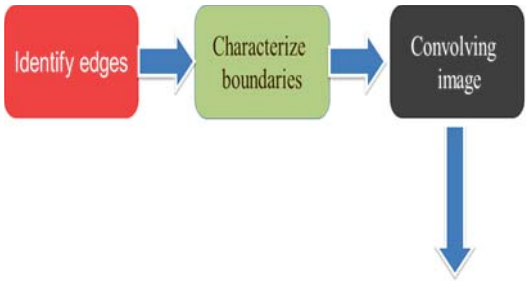

Figure 3 edge detection module

OBJECT IDENTIFICATION MODULE

Image segmentation is the process of partitioning/subdividing a digital image into multiple meaningful regions or sets of pixels regions with respect to a particular application. The segmentation is based on measurements taken from the image and might be grey level, color, texture, depth or motion. The basic steps involves

a**. Filtering**: Images are corrupted by noise such as salt and pepper noise, impulse noise and Gaussian noise. As there is a trade-off between edge strength and noise reduction, filtering is done.

b. **Detection:** Many points in an image have a nonzero value for the gradient, and not all of these points are edges for a particular application. Thresholding is used for the detection of edge points.

Figure 4 object identification module

OBJECT RECOGNITION MODULE

Object recognition involves grouping features related to the same real-world object and extracting the important attributes of these objects.The information captured in an object is position in the image, position in the environment, heading, elevation, orientation and variances over these attributes. Although a sense of elegance might suggest benefits to a clean distinction between feature detection and object recognition it is convenient for the object recognition module to have direct image access.

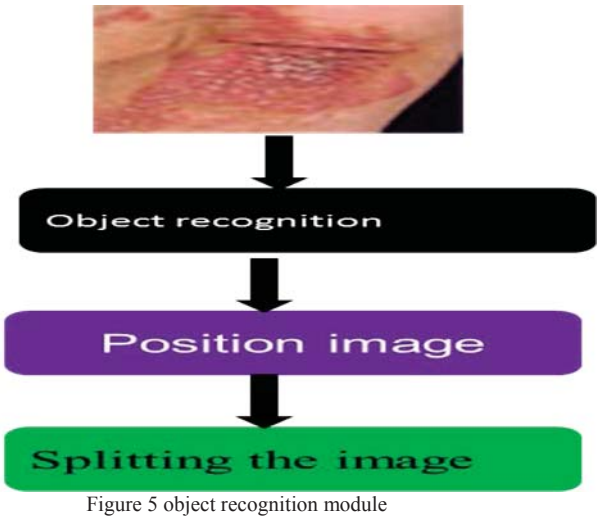

Figure 5 object recognition module

INFECTION DETECTION MODULE

Based on the trained images and objects identified, the system can easily identify the emotion of the particular user. The proposed a 100% accurate system which can identify the users emotion by visually segmenting their images.

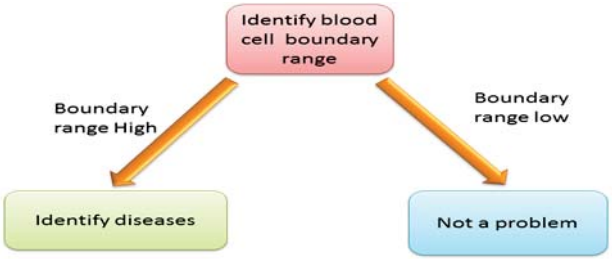

Figure 6 infection detection module

VI. CONCLUSION AND FUTURE ENHANCEMENT

The most common class of drugs inducing these reactions were antibiotic chemotherapeutic agents alone or in combination with other chemotherapeutic drugs. In addition to routine histology, in four patients immune histochemical staining for p53 was performed at the sites of the eruptions after resolution and at noninvolved sites matched for ultraviolet radiation (UVR) exposure. Histologic features in patients receiving concurrent radiation therapy included epidermal dysplasia, keratinocytes showing features of necrosis, increased mitotic figures, and a mixed inflammatory infiltrate. At sites of prior radiation therapy, the biopsy specimens showed a similar spectrum of epidermal changes and, in some cases, psoriasiform dermatitis with clearing within cells in the upper layers of the epidermis. Additional dermal changes included dermal fibrosis, vasodilatation, and atypical fibroblasts. Moderate to marked solar elastosis was seen in the majority of biopsy specimens. Immunohistochemical studies after resolution showed only a modest increase in p53 staining in epidermal keratinocytes in 3 of 4 sites of recall and enhancement eruptions after resolution of the reactions compared to skin that was matched for similar UVR exposure.

REFERENCES

[1] A. J. Mendez, P. G. Tahoces, M. J. Lado, M. Souto, and J. J. Vidal,"Computer-aided diagnosis: Automatic detection of malignant massesin digitized mammograms," *Med. Phys.*, vol. 25, pp. 957–964, Jun.1998.

[2] L. E. Boucheron, "Object- and spatial-level quantitative analysis ofmultispectral histopathology images for detection and characterizationof cancer," Ph.D. dissertation, Dept. Elect. Comput. Eng., Univ. California,Santa Barbara, 2008.

[3] A. Madabhushi, "Digital pathology image analysis: Opportunities andchallenges," *Imag. Med.*, vol. 1, no. 1, pp. 7–10, 2009.

[4] M. N. Gurcan, L. E. Boucheron, A. Can, A. Madabhushi, N. M. Rajpoot,and B. Yener, "Histopathological image analysis: A review,"*IEEE Rev. Biomed. Eng.*, vol. 2, pp. 147–171, 2009.

[5] H. Fox, "Is H&E morphology coming to an end?," *J. Clin. Pathol.*, vol.53, pp. 38–40, 2000.

[6] E. Ozdemir and C. Gunduz-Demir, "A hybrid classification model fordigital pathology using structural and statistical pattern recognition,"*IEEE Trans. Med. Imag.*, vol. 32, no. 2, pp. 474–483, Feb. 2013.

[7] M. Gavrilovic, J. C. Azar, J. Lindblad, C. Wahlby, E. Bengtsson, C.Busch, and I. B. Carlbom, "Blind color decomposition of histologicalimages," *IEEE Trans. Med. Imag.*, vol. 32, no. 6, pp. 983–994, Jun. 2013.

[8] G. Alexe, J. Monaco, S. Doyle, A. Basavanhally, A. Reddy, M. Seiler,S. Ganesan, G. Bhanot, and A. Madabhushi, "Towards improvedcancer diagnosis and prognosis using analysis of gene expression dataand computer aided imaging," *Exp. Biol. Med.*, vol. 234, pp. 860–879,2009.

[9] A. Basavanhally, S. Ganesan, S. Agner, J. P. Monaco, M. D. Feldman,J. E. Tomaszewski, G. Bhanot, and A. Madabhushi, "Computerized image-based detection and grading of lymphocytic infiltration inHER2+ breast cancer histopathology," *IEEE Trans. Biomed. Eng.*, vol.57, no. 3, pp. 642–653, Mar. 2010.

[10] M. M. Dundar, S. Badve, G. Bilgin, V. Raykar, R. Jain, O. Sertel, andM. N. Gurcan, "Computerized classification of intraductal breast lesionsusing histopathological images," *IEEE Trans. Biomed. Eng.*, vol.58, no. 7, pp. 1977–1984, Jul. 2011.

[11] R. M. Haralick, K. Shanmugam, and I. Dinstein, "Textural features forimage classification," *IEEE Trans. Syst., Man, Cybern.*, vol. 3, no. 6,pp. 610–621, Nov. 1973.

[12] J. Serra, *Image Analysis and Mathematical Morphology*. NewYork:Academic, 1982.

[13] F. Zana and J.-C. Klein, "Segmentation of vessel-like patterns usingmathematical morphology and curvature evaluation," *IEEE Trans.Image Process.*, vol. 10, no. 7, pp. 1010–1019, Jul. 2001.

[14] O. Chapelle, P. Haffner, and V. N. Vapnik, "Support vector machinesfor histogram-based image classification," *IEEE Trans. Neural Netw.*,vol. 10, no. 5, pp. 1055–1064, Sep. 1999.

[15] A.Wetzel, R. Crowley, S. Kim, R. Dawson, L. Zheng, Y. Joo, Y. Yagi,J. Gilbertson, C. Gadd, D. Deerfield, and M. Becich, "Evaluation ofprostate tumor grades by content based image retrieval," in *Proc. SPIE*,1999, vol. 3584, pp. 244252.